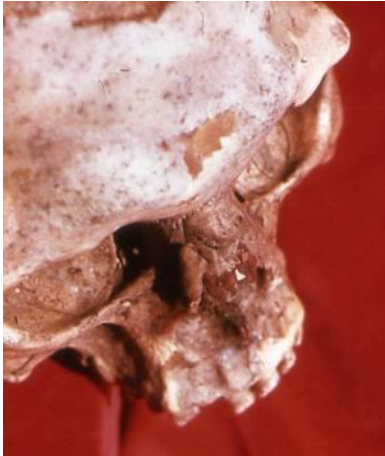
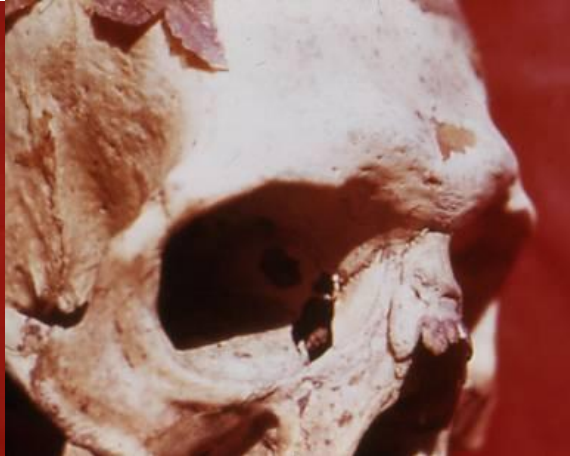
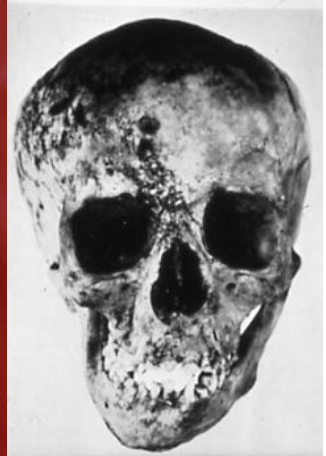FRACTURES & WOUNDS



A 2



A 3

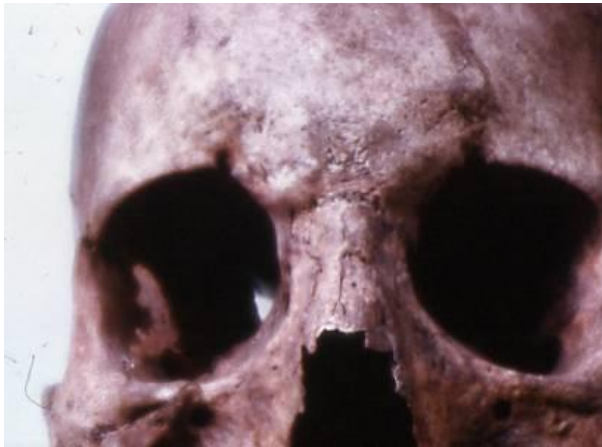

A 5

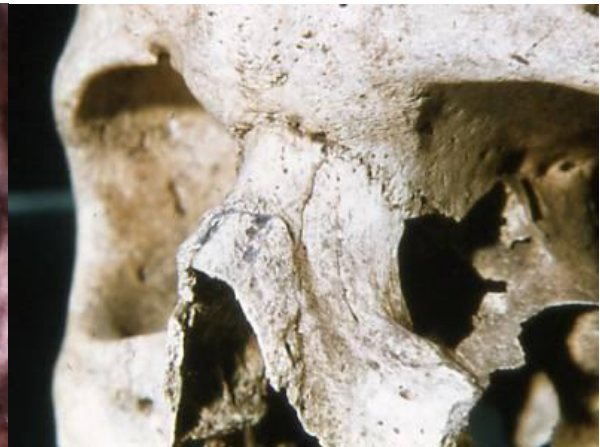A 2 : Fracture nose + osteitis / Egypt

A 3 : Fracture nose + osteitis / Egypt

A 5 : Fronto-facial fracture + asymmetry / Nubian



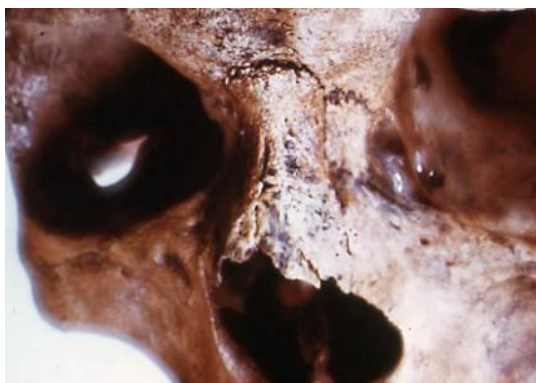A 6



A 7

A 6 : Fracture nose / Thetford3 / Anglo-Saxon

A 7 : Fracture nose / Thetford3 / Anglo-Saxon



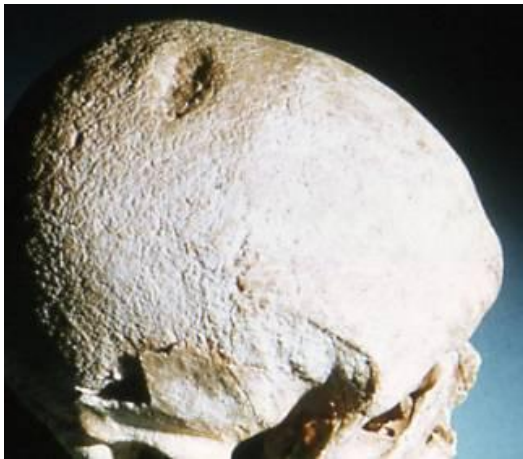
A 8



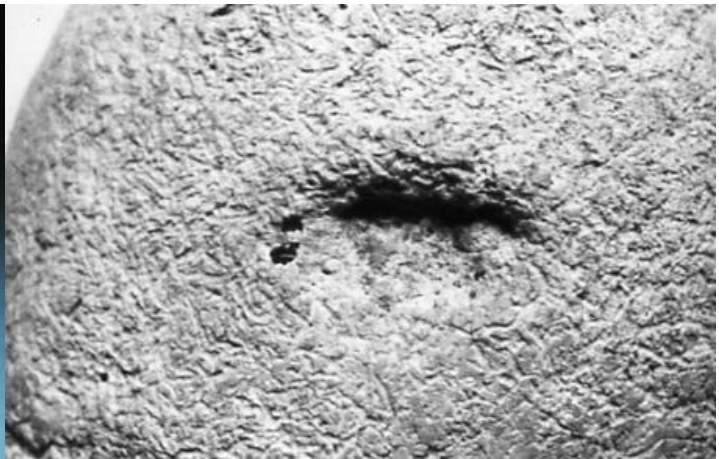A 12

A 8 : Fracture nose / Thetford 18 / Anglo-Saxon

A 12 : Fracture skull / Cadoc's / Llancarlan



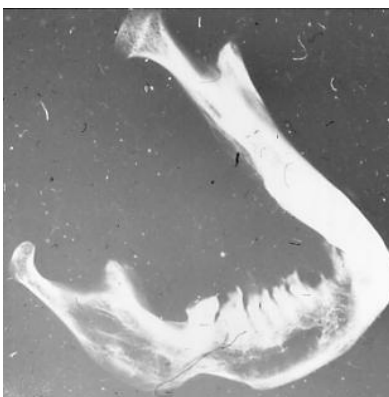
A 13



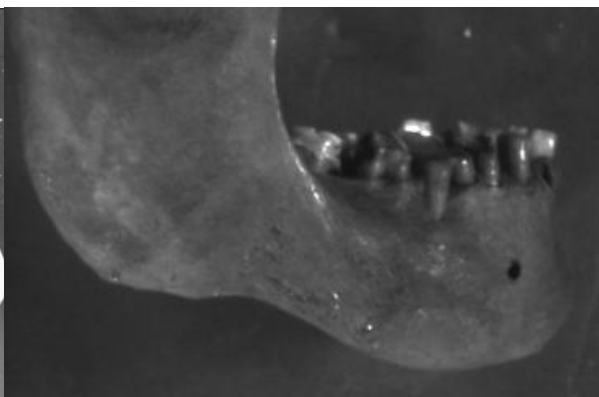
A 14

A 13 : Fracture skull / W ighton / Norfolk

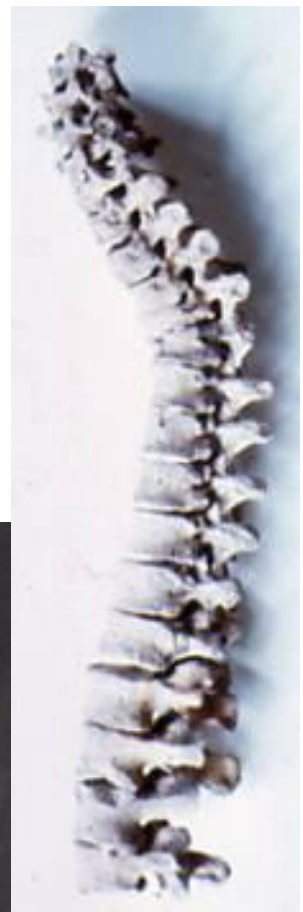A 14 : Fracture skull / W ighton / Norfolk



A 18



A 19

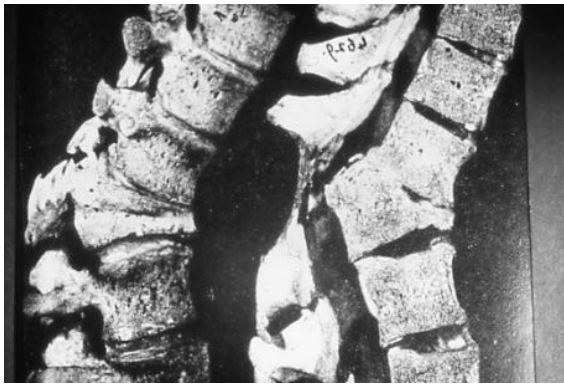

A 26

A 18: Fracture mandible (X-ray) / Egypt

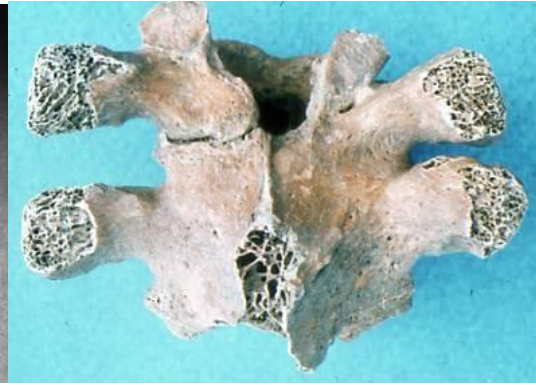A 19 : Fracture mandible (X-ray)/ Egypt

A 26 : Fracture vertebrae / Cirencester / Romano-British



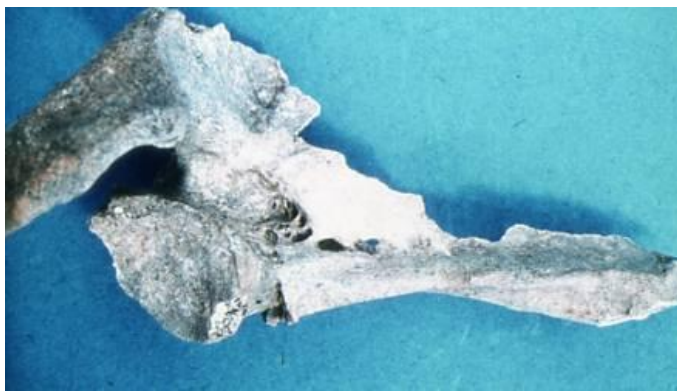
A 27

A 27: Fracture T12 + collapse



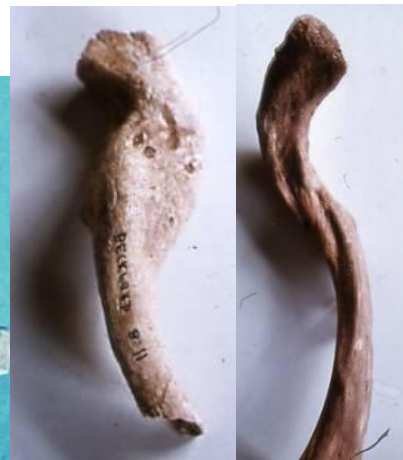A 28

A 28 : Fracture + synostosis T3/T4 / Romano-British



A 31

A 31: Fracture right scapula / Anglo-Saxon



A 32

A 32: Fracture clavicle / Backford / Anglo-Saxon

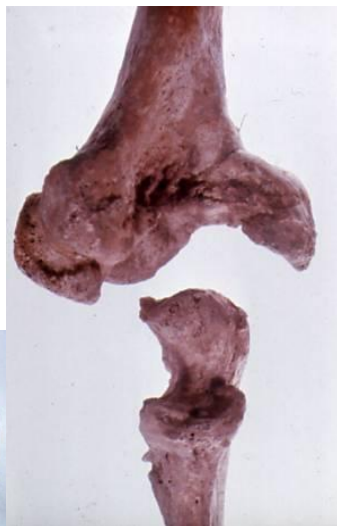A 33

A 33: Fracture clavicle / Backford / Anglo-Saxon



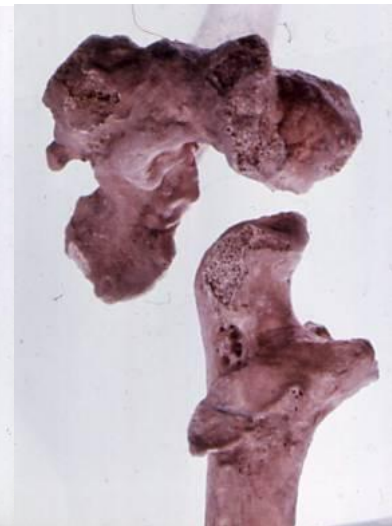A 34

A 34: Fracture clavicle / Norwich / Post MA



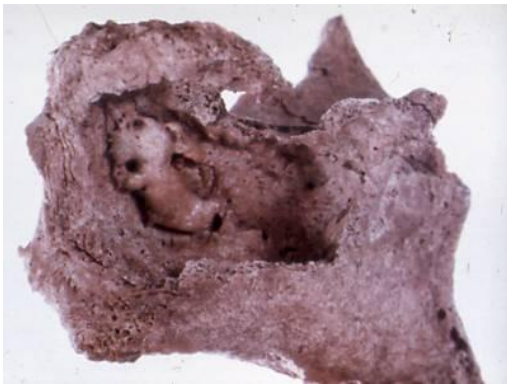A 35

A 35 : Fracture-dislocation elbow / Hartlepool

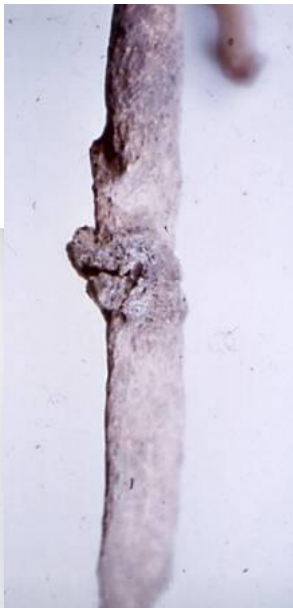

A 36

A 36 : Fracture-dislocation elbow / Hartlepool



A 37



A 38

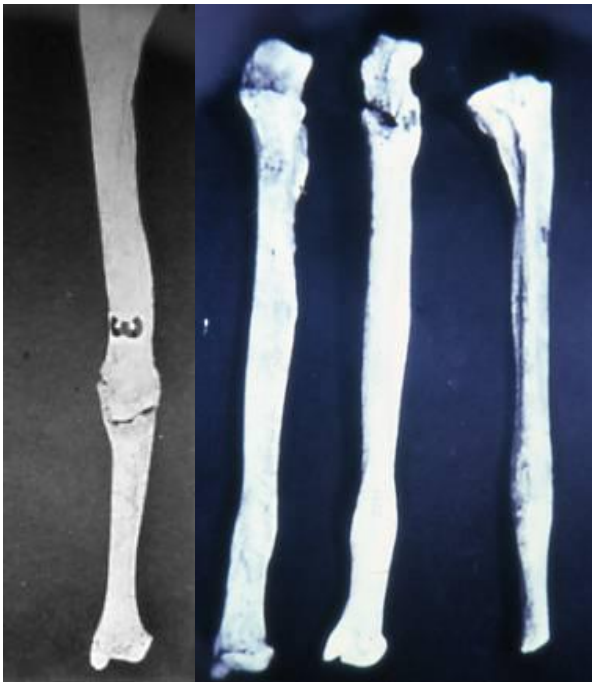


A 39

A 37: Fracture dislocation elbow / Hartlepool Inh A

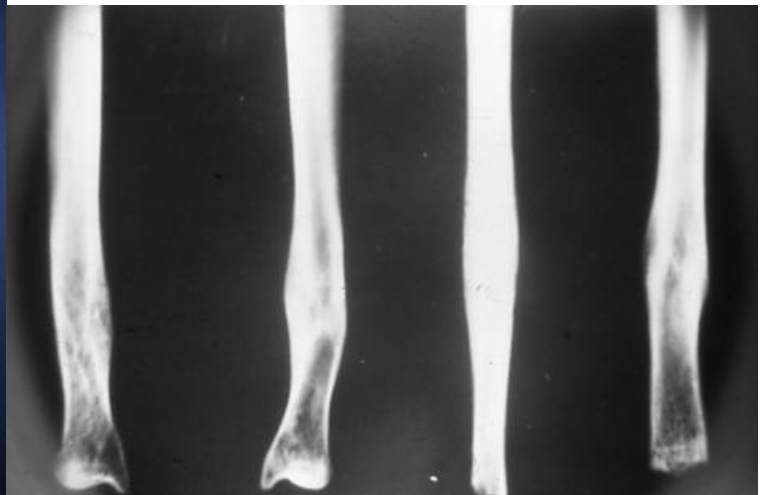A 38 : Fracture ribs / Thetford / Anglo-Saxon

A 39 : Fracture clavicle & 17 fractures in 16 ribs



A 41

A 42

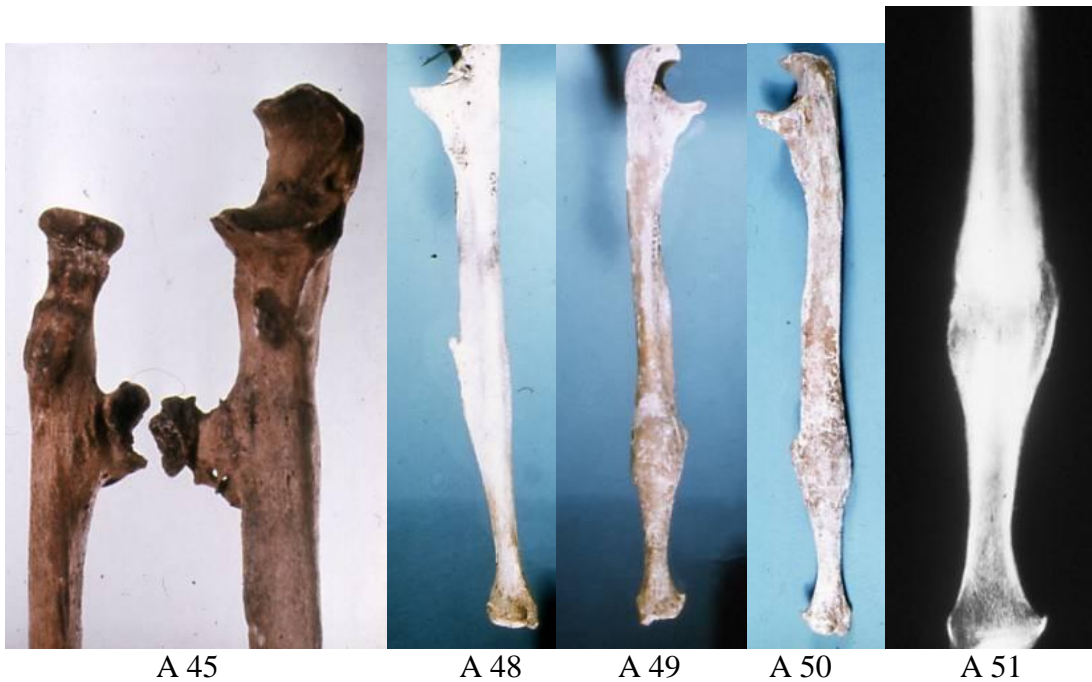

A 43

A 41: Fracture + pseudarthrosis ulna / Illinois

A 42 : Parry's fracture / Furfooz / Neolithic

A 43 : Parry's fracture (X-ray)/ Furfooz / Neolithic



A 45

A 48

A 49

A 50

A 51

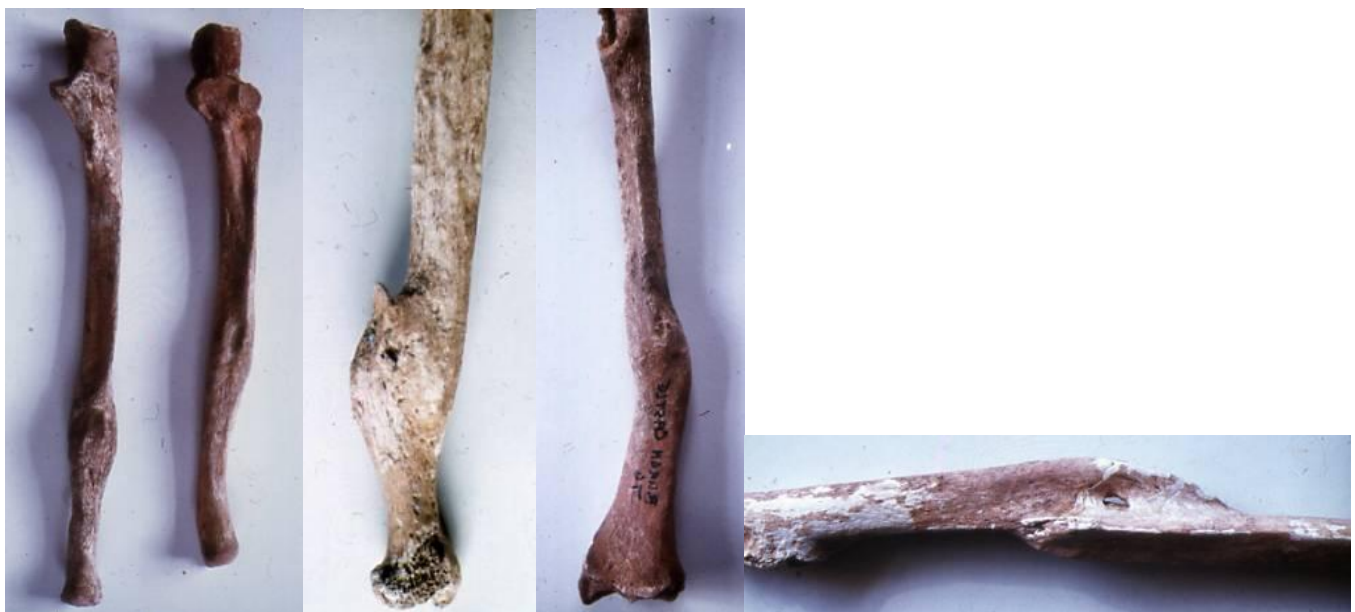A 45 : Fracture ulna+radius : failed cross union / Roman-British [cf. D 170-172]

A 48: Parry's fracture

A 49 : Parry's fracture / Thetford Priory / Anglo-Saxon

A 50: Parry's fracture / Thetford Priory

A 51 : Parry's fracture(X-ray)/ Thetford Priory / Anglo-Saxon



A 52

A 53

A 56

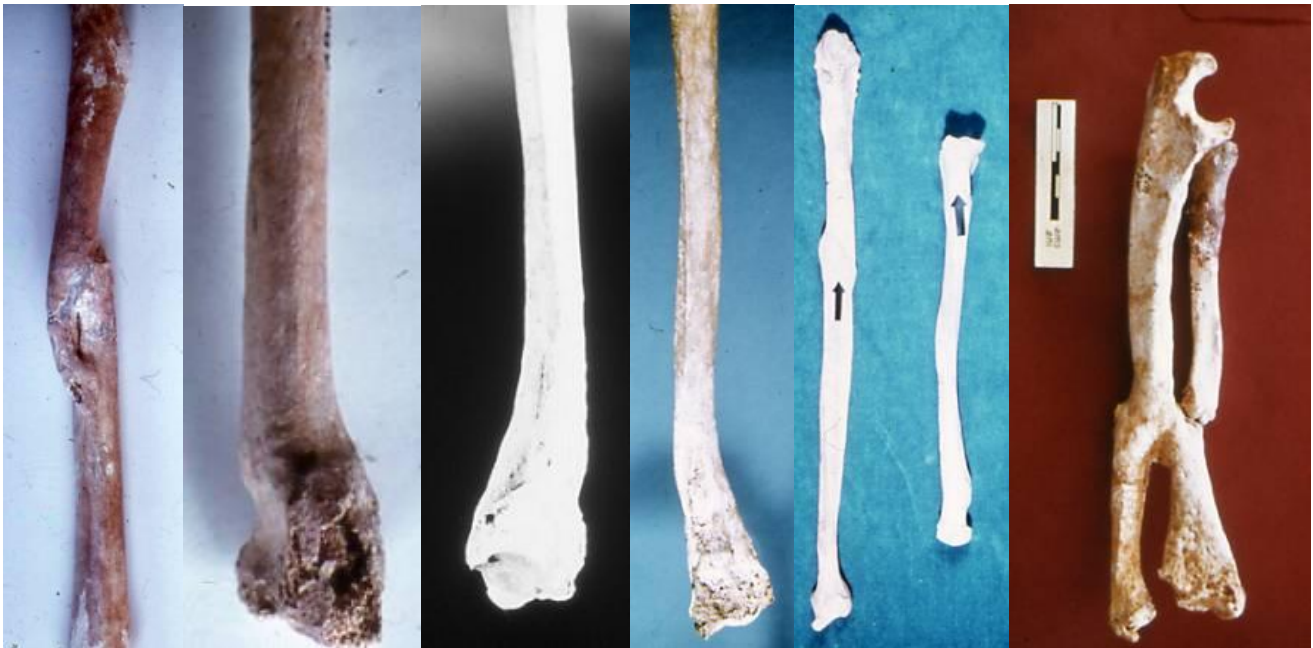A 57

A 52 : Parry's fracture / Mundford

A 53 : Fracture ulna / Cirencester / Romano-British

A 56 : Fracture radius / Burgh Castle / Anglo-Saxon

A 57 : Fracture radius / Verulamium / Romano-British



A 58

A 59

A 60

A 61

A 62

A 65

A 58 : Fracture radius / Verulamium / Romano-British

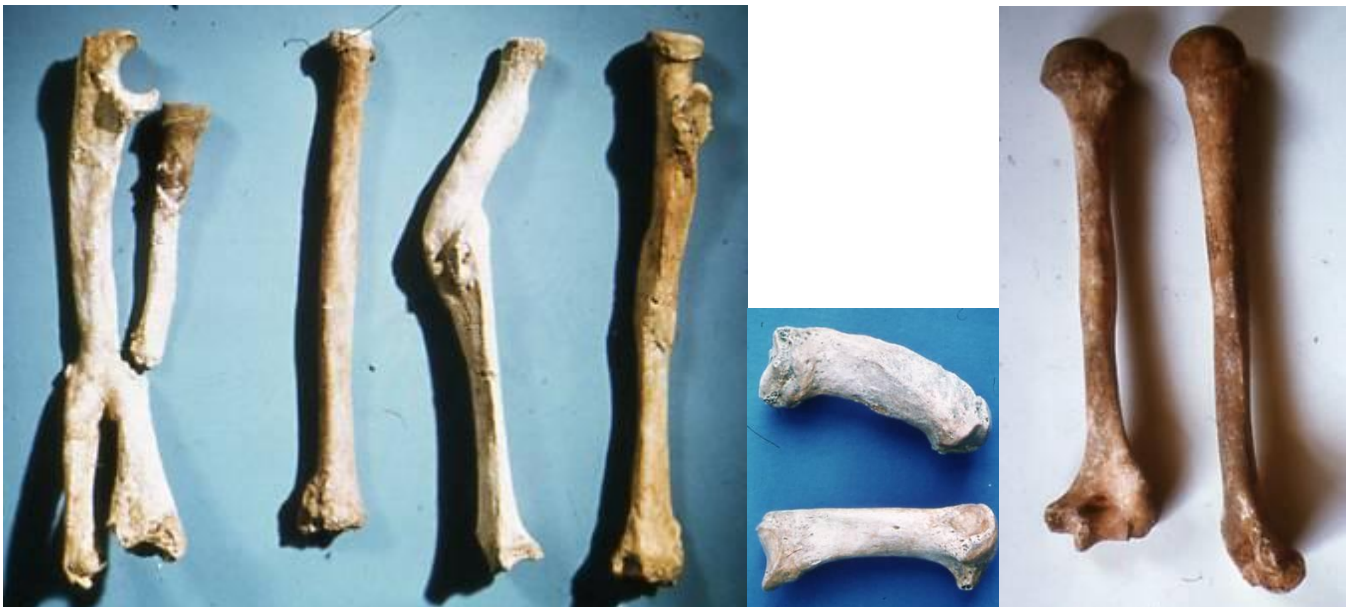A 59 : Colles' fracture / Iona

A 60 : Colles' fracture (X-ray)

A 61 : Colles's fracture

A 62 : Colles's and Pott's fractures combined

A 65 : Fracture ulna + radius : cross union and pseudarthrosis



A 66

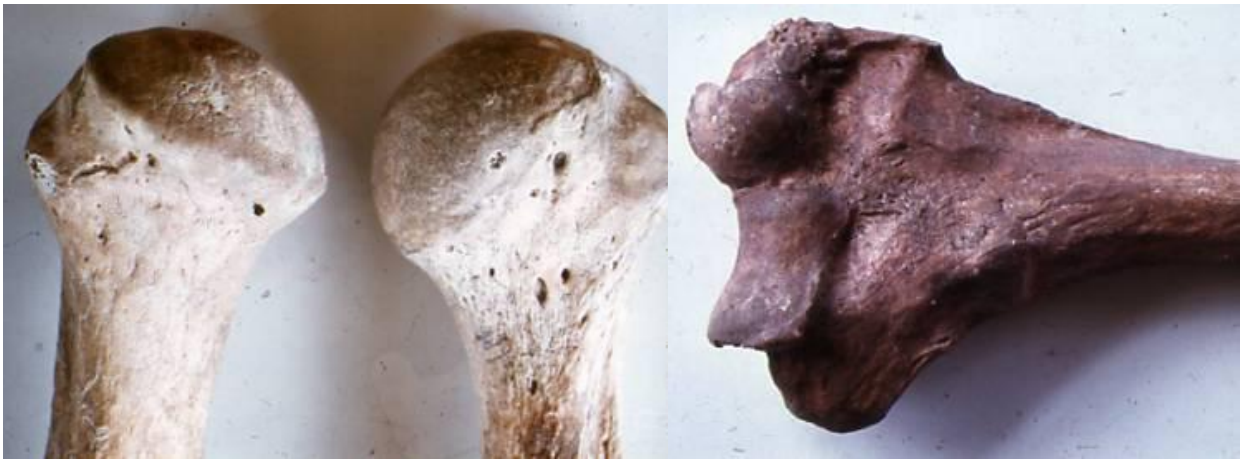A 67

A 71

A 66 : Colles' & Pott's fractures combined

A 67 : Fracture first metacarpal

A 71 : ? Fracture humeral epiphysis / Mundford / Romano-British



A 72

A 75

A 72 : ? Fracture humeral epiphysis / Mundford / Romano-British

A 75 : Fracture humeral supra condylar / Thetford

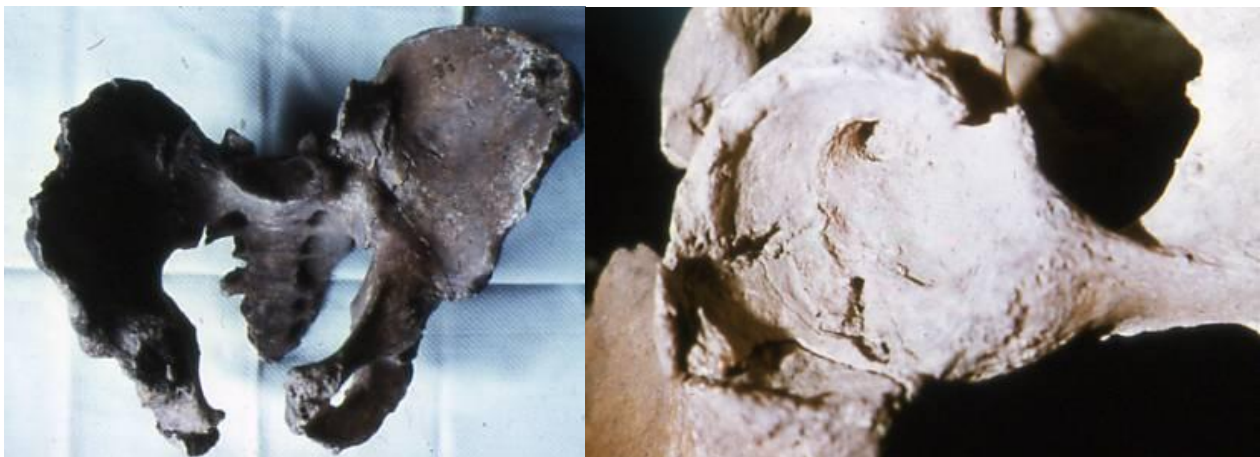

A 79

A 80

A 79 : Fracture-dislocation pelvis / Mk66UK31 / Anglo-Saxon

A 80 : Fracture-dislocation sacral ala / Mk66UK31 / Anglo-Saxon




A 81

A 82

A 81 : Fracture dislocation pelvis sacral ala / Mk66UK31 / Anglo-Saxon

A 82 : Fracture acetabulum / Mk66UK31 / Anglo-Saxon



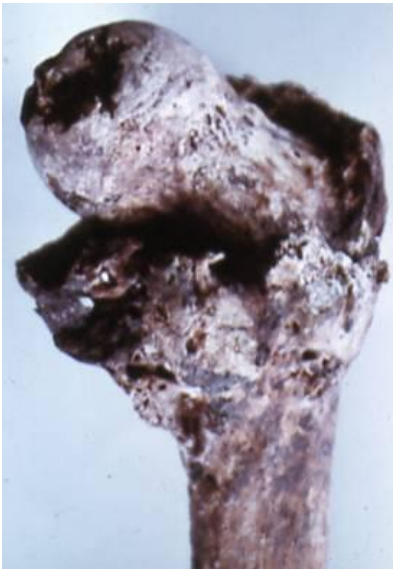A 83



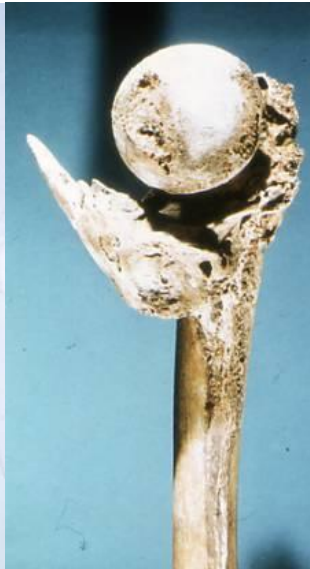A 84

A 83 : Fracture femur neck femur "b" / Mk66UK31 / Anglo-Saxon

A 84 : Fracture femur / Mk66UK31 / Anglo-Saxon



A 88



A 89



A 90



A 91

A 88 : Fracture femur neck / Norwich / 17th - 18th century

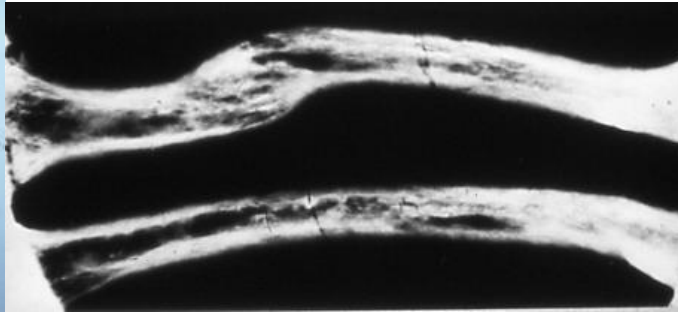
A 89 : Fracture femoral neck + exostosis / Norwich / 17th-18th century

A 90 : Fracture femoral neck + exostosis / Norwich / 17th-18th century

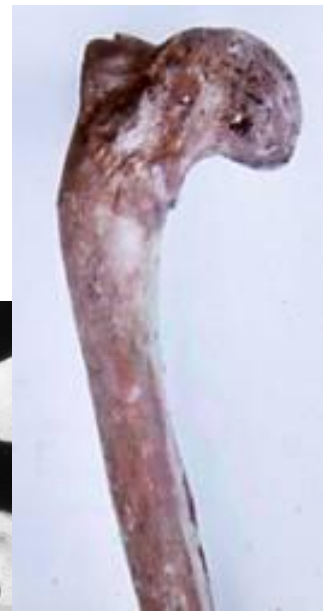A 91 : Fracture femur shaft / Burgh Castle / Anglo-Saxon



A 92



A 93



A 96

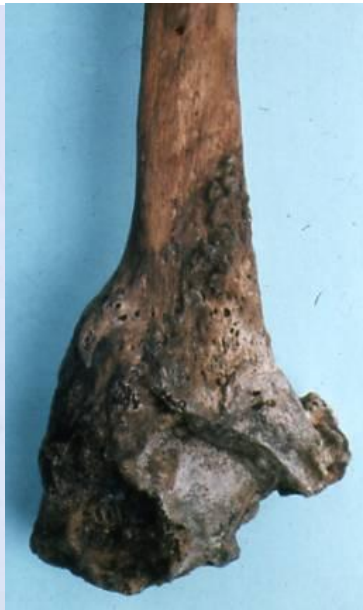A 92 : fracture femur + Paget's disease / Jarrow

A 93 : Fracture femur + Paget's disease (X-ray) / Jarrow

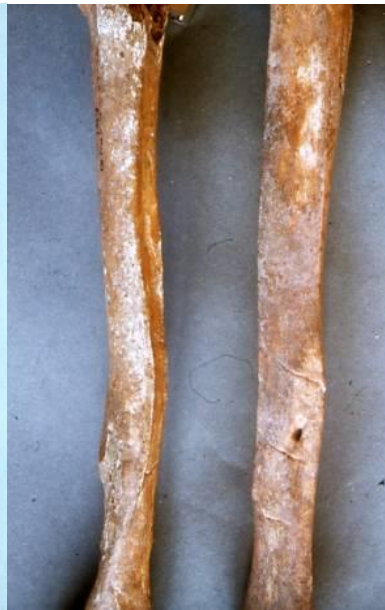A 96 : Fracture femur supra condylar / Norwich / 17th-18th century



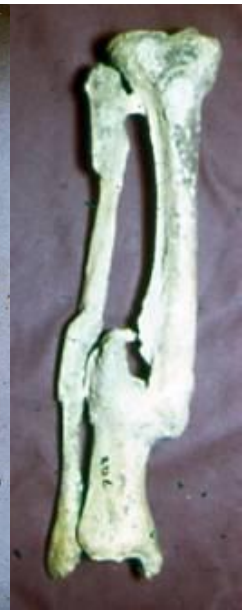A 97



A 98



A 99



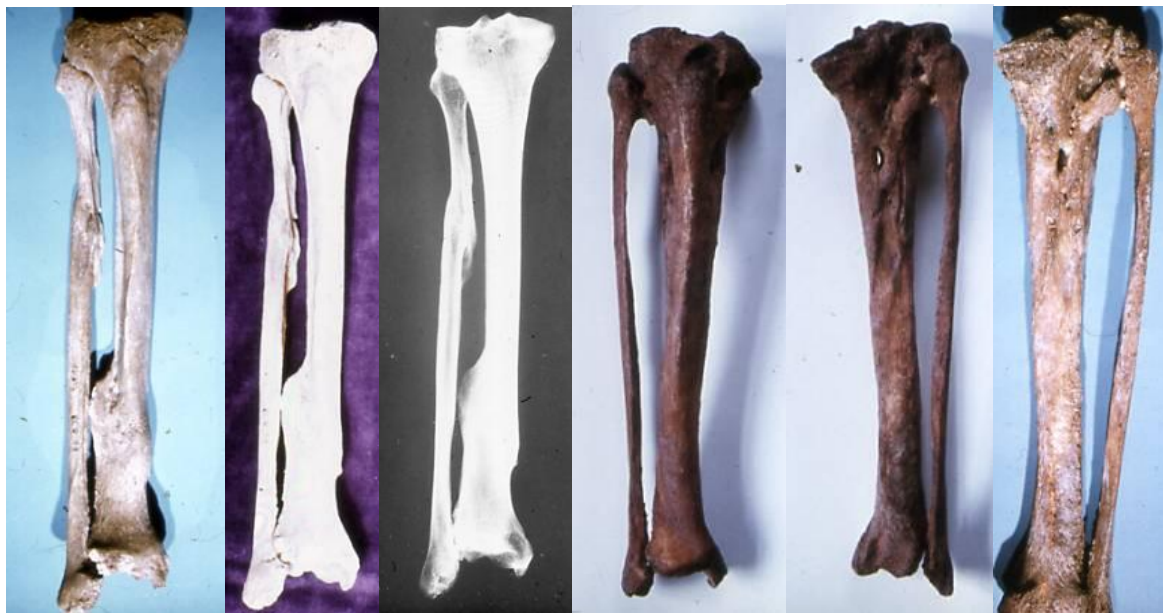A 100

A 97 : Fracture femur supra condylar / Norwich / 17th-18th century

A 98 : Fracture fibula distal / Norwich / 17th-18th century

A 99 : Fracture tibia sinus-vascular grooves

A 100 : fracture tibia & fibula / Egypt



A 101

A 102

A 103

A 104

A 105

A 106

A 101: fracture tibia & fibula /Thetford / Anglo-Saxon

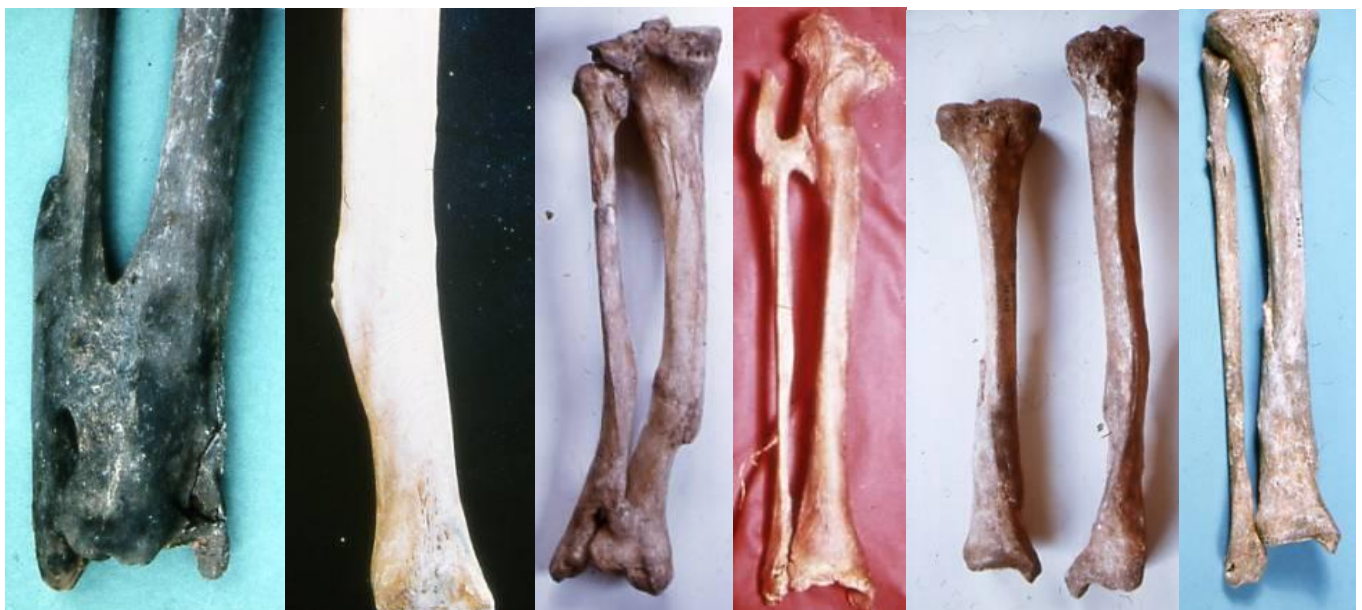A 102 : Fractures tibia & fibula /Thetford / Anglo-Saxon

A 103 : Fractures tibia & fibula (x-ray) / Thetford / Anglo-Saxon

A 104 : Fractures tibia & fibula / Norwich / 17th-19th centuries

A 105 : Fractures tibia & fibula+ synostosis / Norwich / 17th-19th centuries

A 106 : Fractures tibia & fibula+ synostosis / Norwich / 17th-19th centuries



A 107

A 108

A 109

A 110

A 111

A 112

A 107 : Fractures tibia & fibula+ synostosis / Icklingham

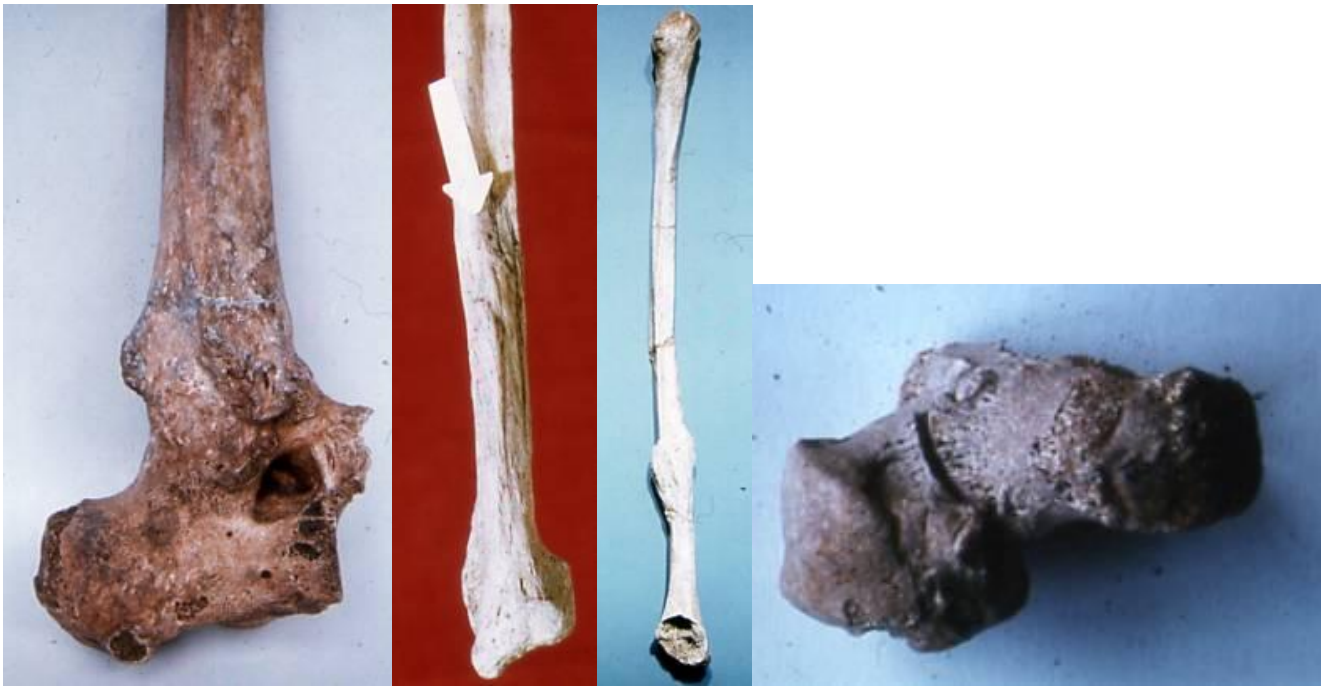A 108 : ? Fractures tibia / Burgh-Castle / Anglo-Saxon

A 109 : Fractures tibia & fibula / Cirencester

A 110 : Fractures tibia & fibula

A 111 : Fractures tibiae / Pocktorpe / Burgh-Castle

A 112 : Fractures tibia & fibula / Pocktorpe



A 114

A 115

A 116

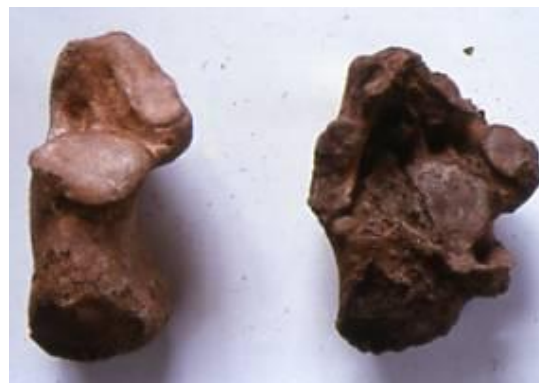A 117

A 114: Fractures tibia-talus-calcaneus synostosed

A 115 : Fracture fibula / Coxlane Ipswich / Medieval

A 116: Fracture fibula / Owsleburg

A 117: talus & calcaneus ankylosed / Iona

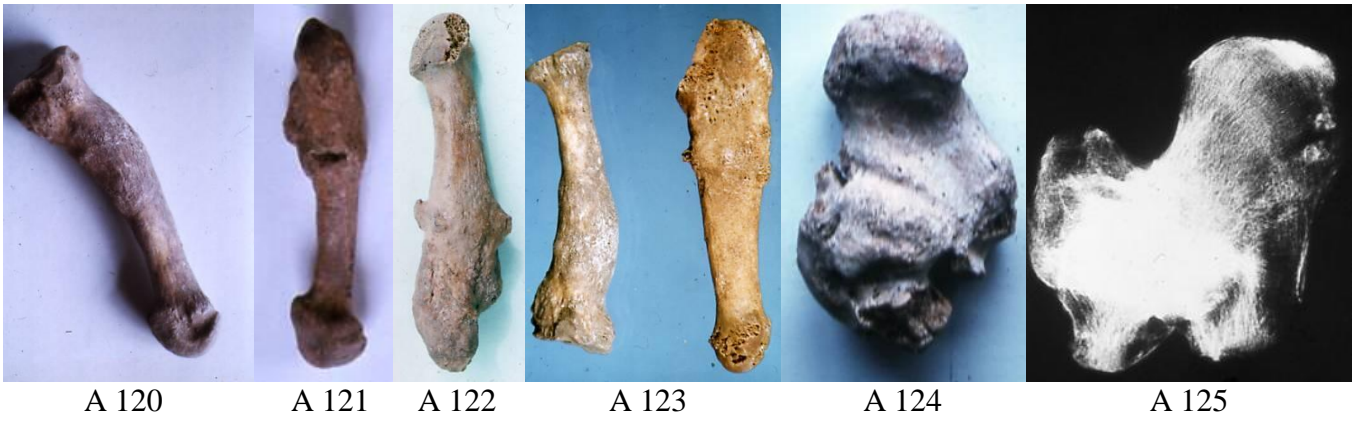


A 118



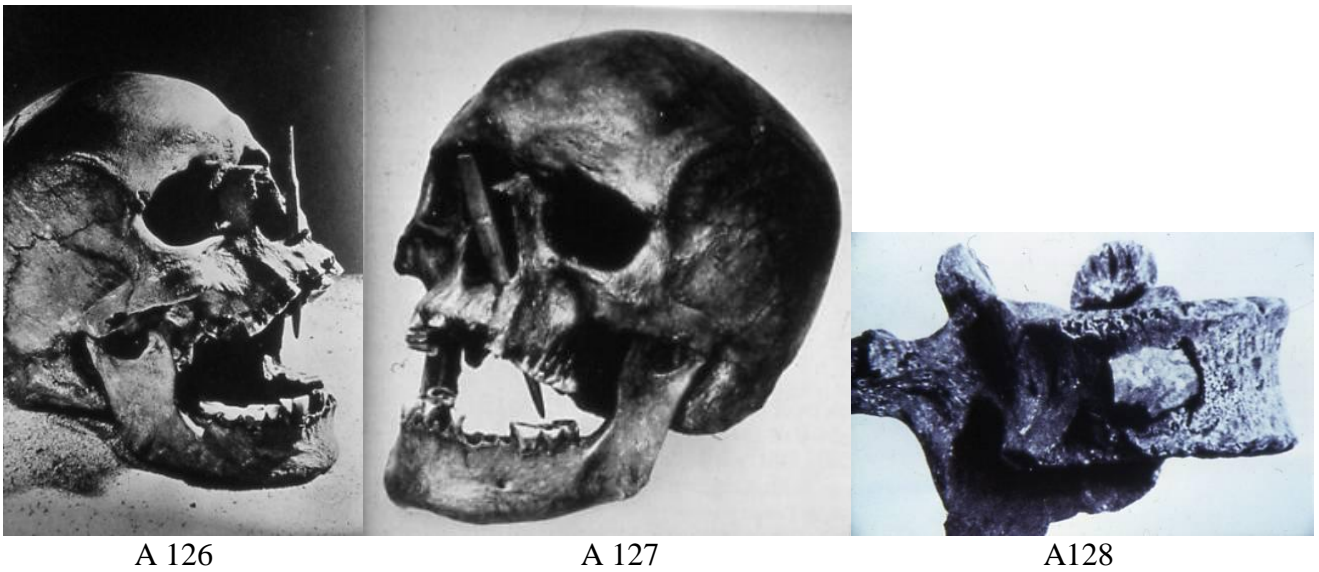
A 119

A 118 & A 119 : Fracture calcaneus / Norwich / 17th-19th centuries

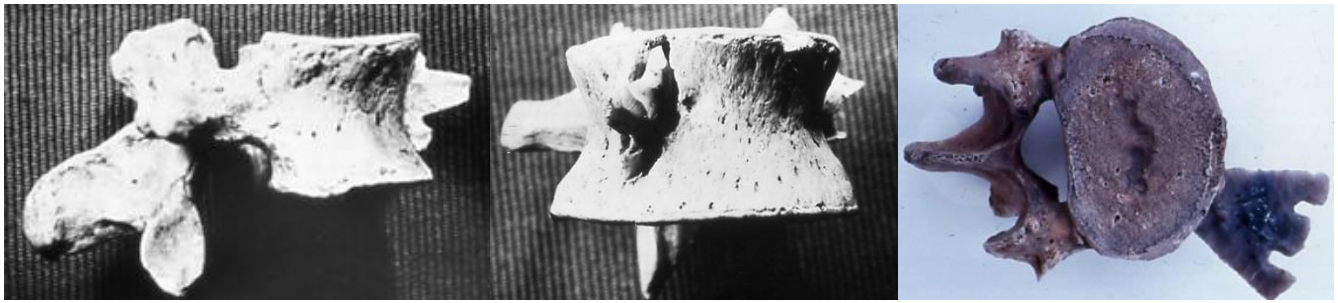


- A 120 : *fracture metarsal / N.E.P./ Anglo-saxon*
- A 121: *fracture metarsal +(?)wound / Jarrow*
- A 122: *Fracture metatarsals / Shouldham*
- A 123 : *Fracture metatarsals / Shouldham*
- A 124 : *Fracture talus & calcaneus ankylosed / Iona*
- A 125: *Fracture talus & calcaneus ankylosed(x-ray) / Burgh-Castle*

Wounds



- A 126: *Arrow head in palate / Porsmose*
- A 127: *Arrow head in palate / Neolithic*
- A 128 : *Arrowhead in vertebra / Lozere*



A 129


A 130

A 131

A 129 : Arrowhead in vertebra / Toulouse

A 130 : Arrow head in vertebra / Toulouse

A 131 : Arrowhead in vertebra / Neolithic



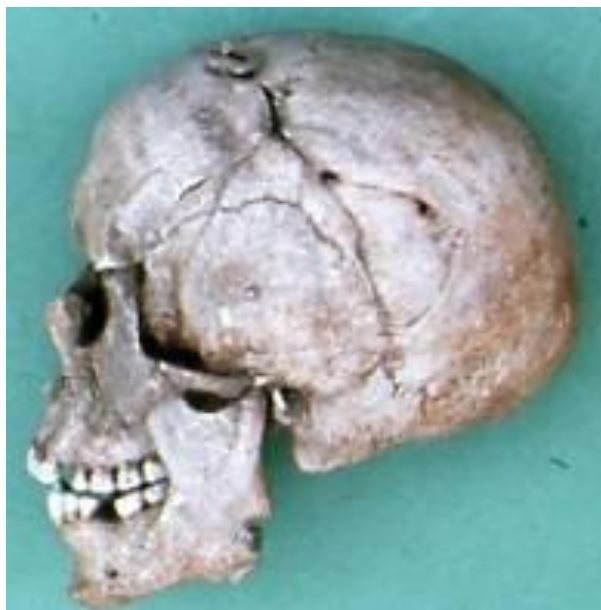A 132



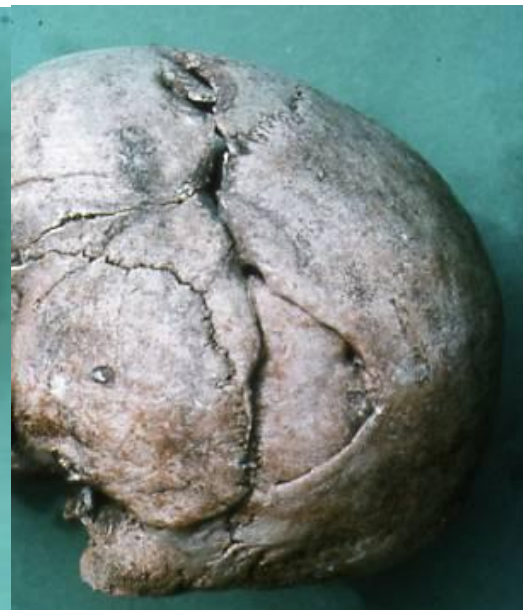A 133

A 132: Arrow head in vertebra / Neolithic

A 133 : Arrowhead in vertebra



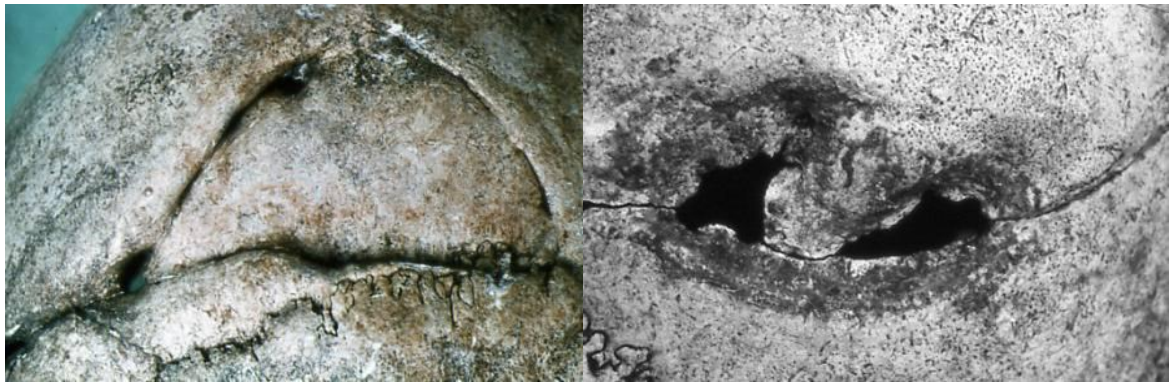A 134



A 135

A 134: Wound of skull & trephination / Ciren 305

A 135: Wound of skull / Ciren 305

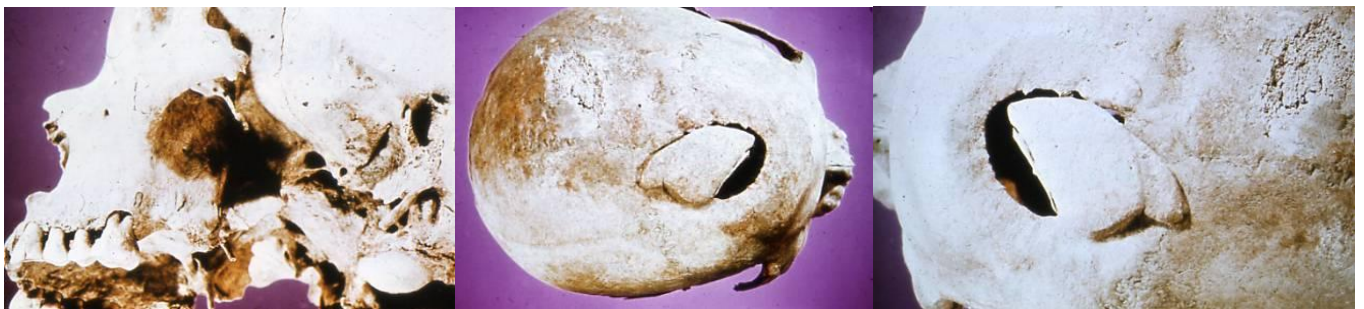

A 136

A 137

A 136 : Wound of skull / Ciren.305 (cf. A 155 - 156)

A 137 : Trephination / Ciren 305



A 138

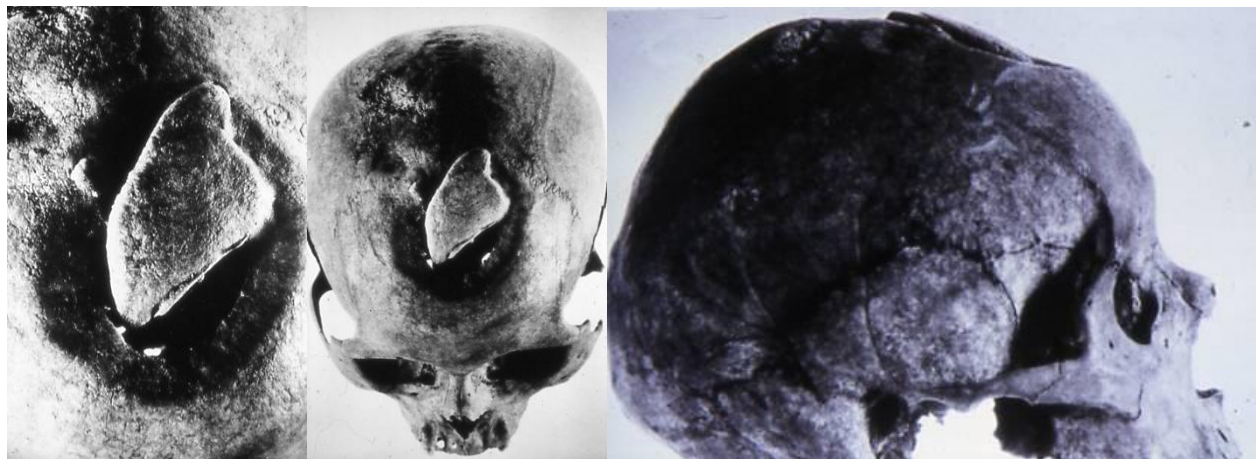
A 139

A 140

A 138 : Wounded skull / Ontario / Petun

A 139: Wounded skull / Ontario / Petun

A 140 : Wounded skull / Ontario / Petun



A 141

A 142

A 143

A 141 : Wounded skull / Ontario / Petun

A 142 : Wounded skull / Ontario / Petun

A 143 : Wounded skull / Ontario / Petun



A 144

A 146

A 147

A 148

A 144 : Wounded skull (x-ray) / Ontario / Petun

A 146: Starheaded mace & skull wound / Peru

A 147 & A148: Starheaded mace wound



A 151

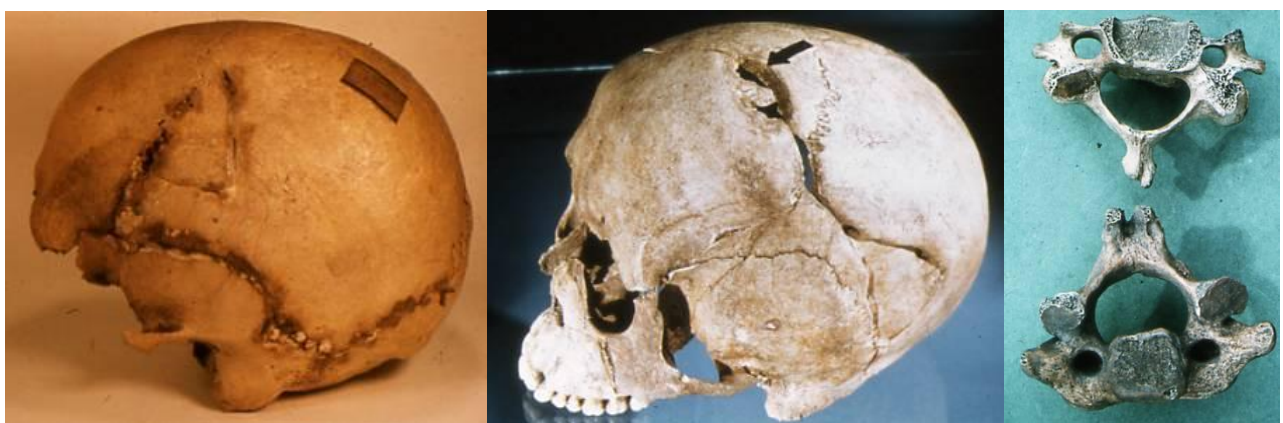A 152

A 153

A 151: Wound of frontal / Cirencester / Romano-British

A 152: ?Slingshot wound / Cirencester / Romano-British

A 153: Wounded mandible / Hellesdon



A 154

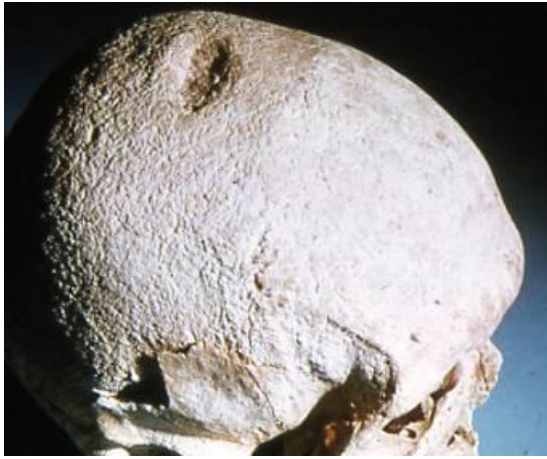A 155

A 156

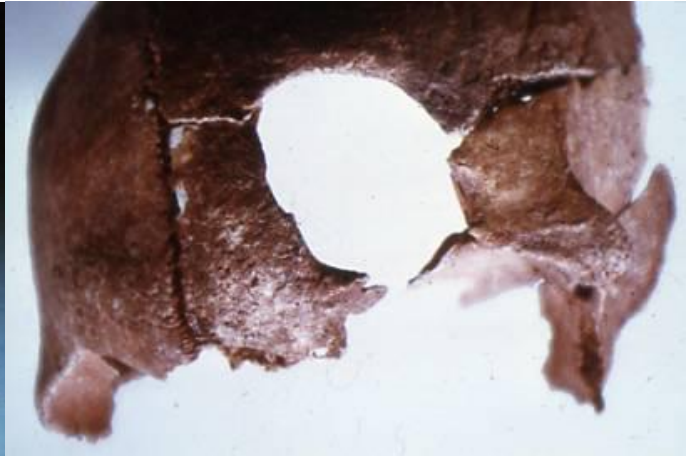
A 154 : Wounded skull

A 155 : Wounded skull + ? trephination / Romano-British (cf. A 134-137 & A 198-199)

A 156 : Decapitation C2/C3 / Ciren.305 (cf. A 134-137 & A 198-199)



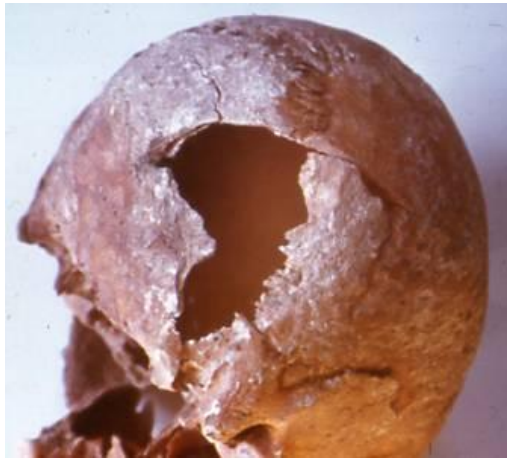A 158



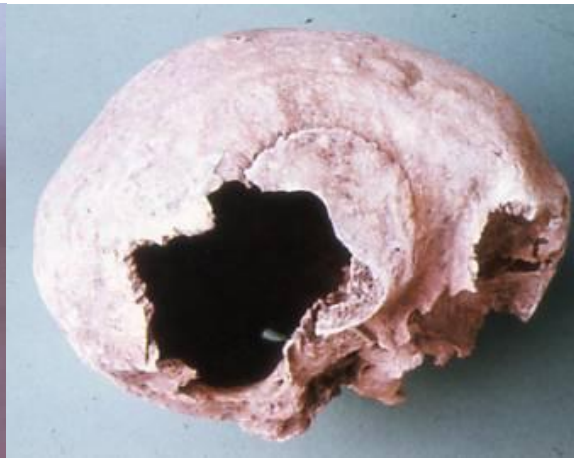A 161

A 158 : ?Slingshot wound /Wighton

A 161 : Wound of frontal / Beckford / Anglo-Saxon



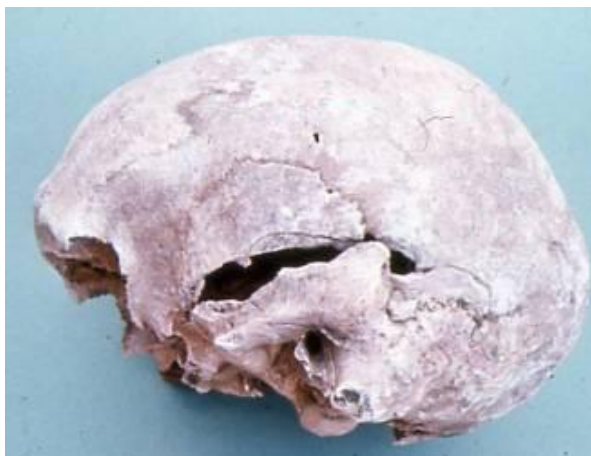A 162



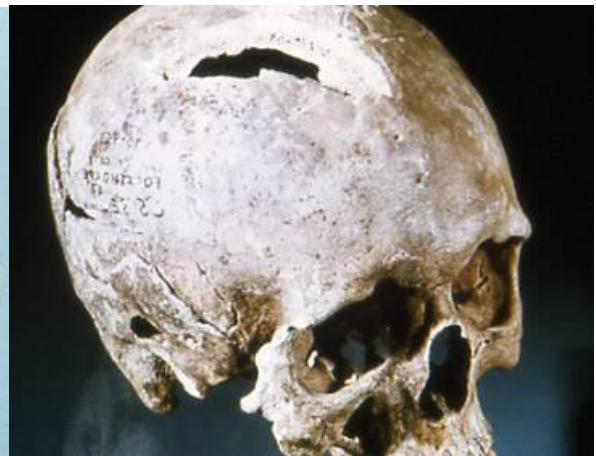A 163

A 162: Wounded skull / Burgh Castle/ Anglo-Saxon

A 163 : Wounded skull / N.E.P. 171 / Anglo-Saxon



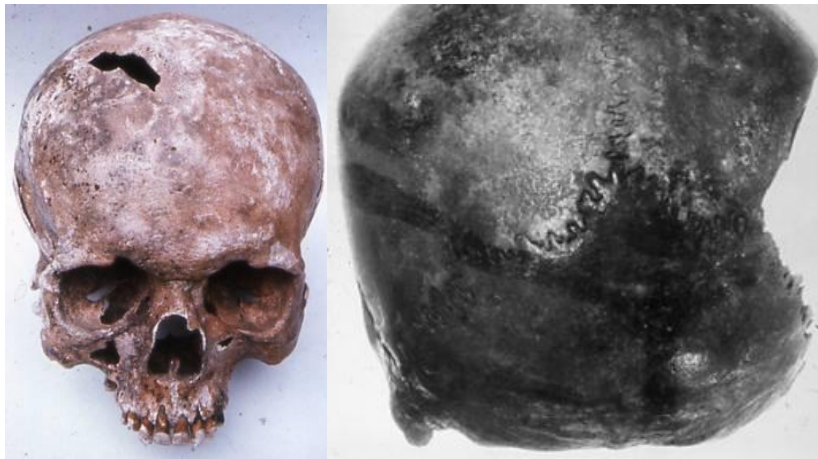
A 164



A 168

A 164 : Wounded skull / N.E.P. 171 / Anglo-Saxon

A 168 : Wounded skull / Peclerthorpe / Anglo-Saxon

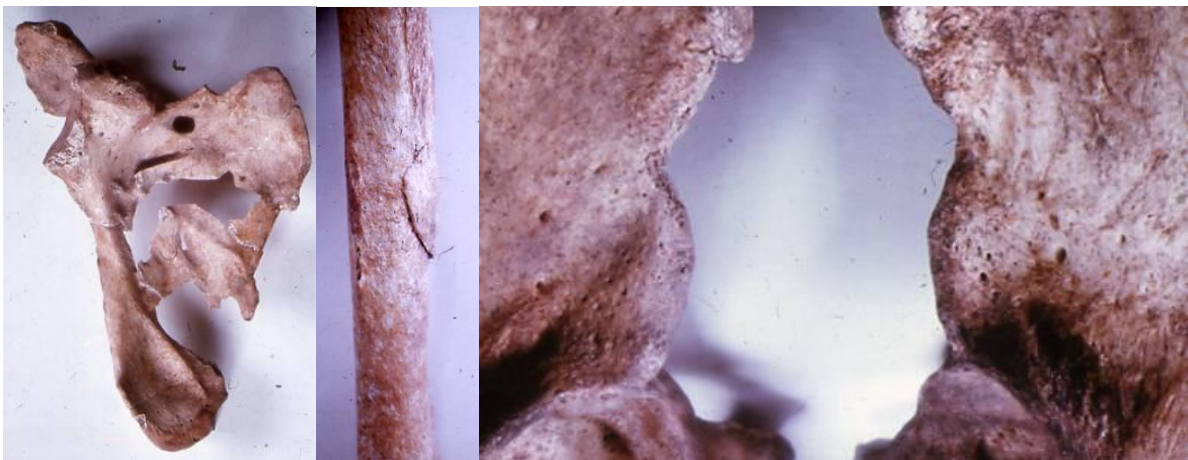


A 169

A 170

A 169 : Wounded skull / Pockthorpe / Anglo-Saxon

A 170 : Wounded skull / Wainford



A 173

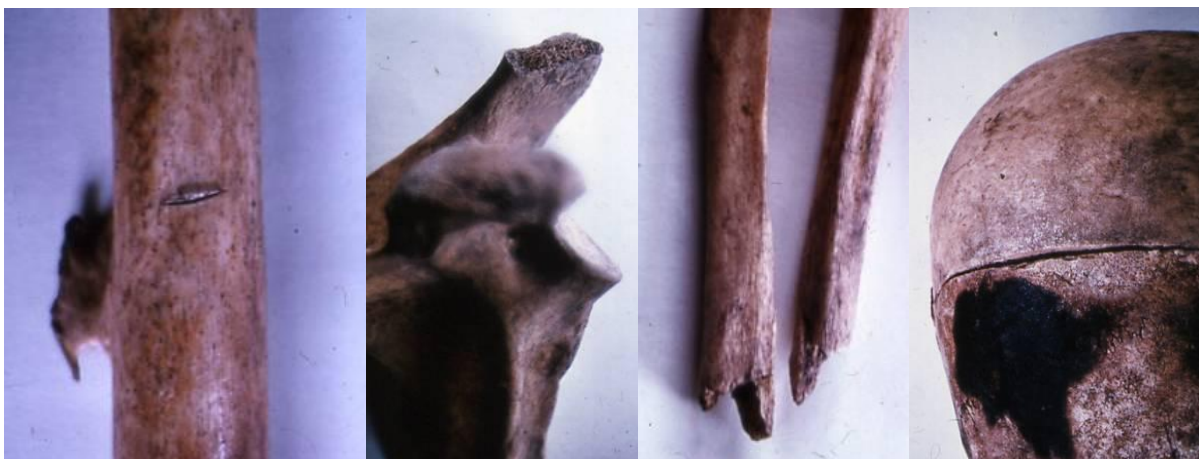A 174

A 179

A 173 : ? fracture- wounded scapula / Ciren / Romano-British

A 174 : Wound of humerus / Ciren / Romano-British

A 179 : Wounded ilium / Cox Lane, Ipswich



A 180

A 181

A 182

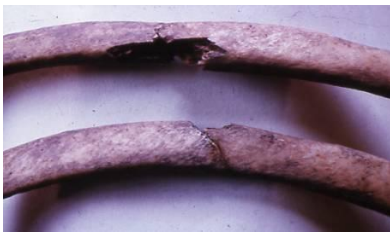A 183

A 180 : Wounded femur / Rider's bone / Ipswich

A 181 : Wounded scapula / Cox Lane, Ipswich

A 182 : Amputated forearm / Cox Lane, Ipswich

A 183 : Wounded skull / Cox Lane, Ipswich



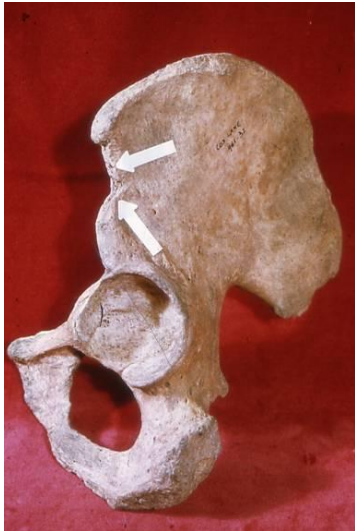A 184



A 185

A 184 : Wounded ribs / Cox Lane / Ipswich

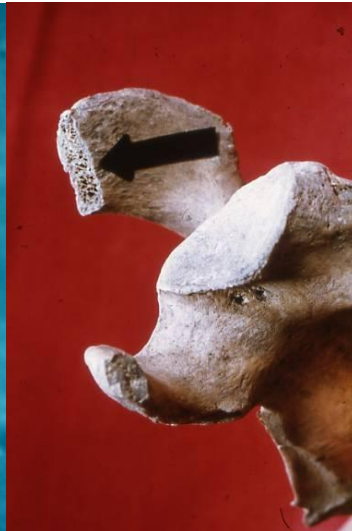A 185 : Murdered man / Cox Lane, Ipswich



A 186



A 187



A 188

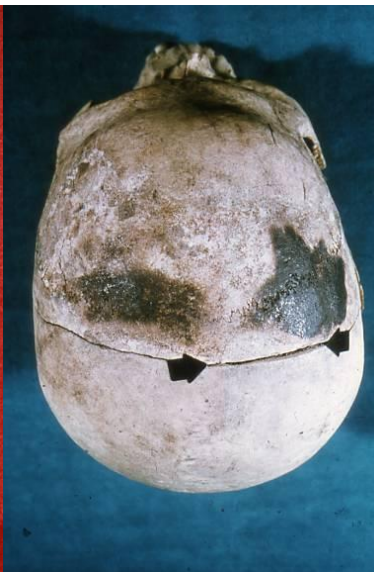A 186 : Wounded ilium / Cox Lane / Ipswich

A 187 : Wounded femur / Rider's bone / Cox Lane, Ipswich

A188 : Wounded acromion / Cox Lane / Ipswich



A 189



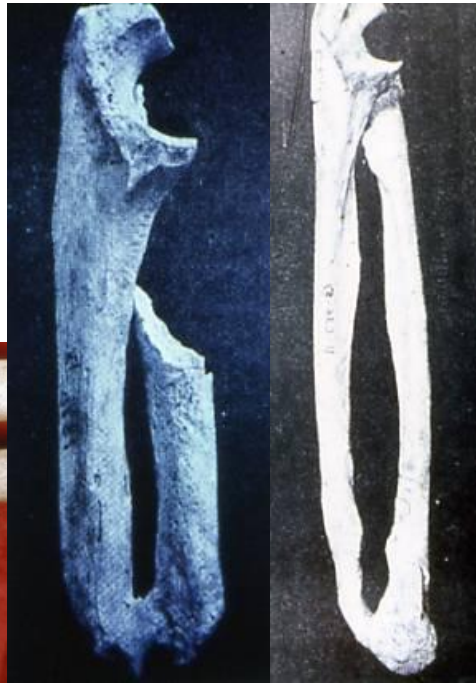A 190

A 189 : Amputated forearm / Cox Lane / Ipswich

A 190 : Wounded skull / Cox Lane / Ipswich



A 191



A 194

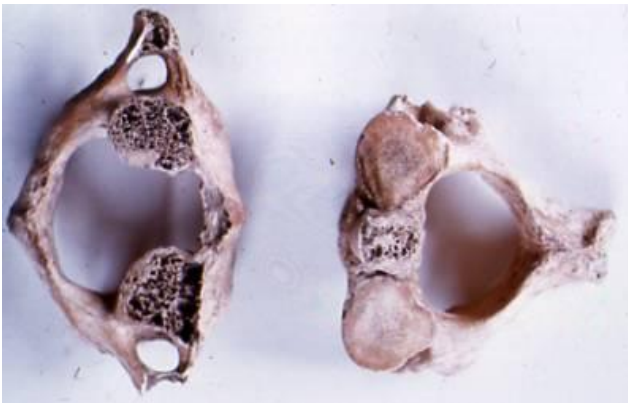
A 195

A 190 : Wounded skull / Cox Lane / Ipswich

A 191 : Wounded ribs / Cox Lane, Ipswich

A 194 : Amputated forearm / Egypt

A 195 : Amputated hand / Hopewell Culture



A 198



A 199

A 198 : Decapitation / Cirencester, Inh R / Romano-British

A 199 : Decapitation / Cirencester, Inh R / Romano-British