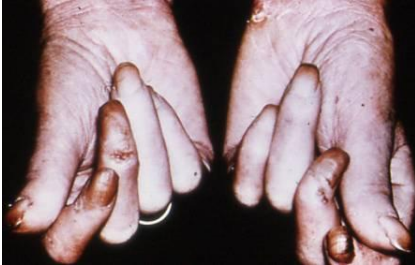
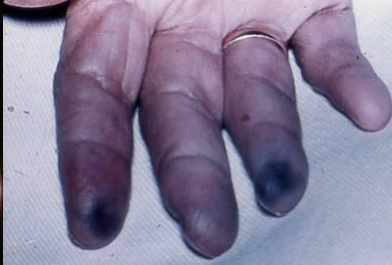
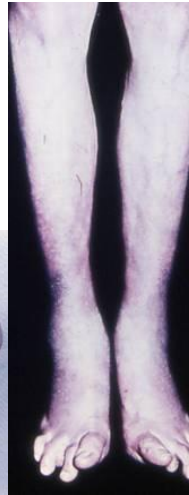
Maps, Graphs, Tables, Clinical slides



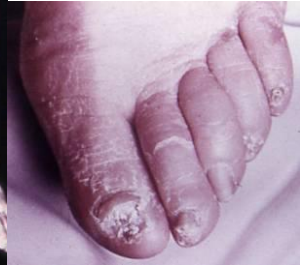K61



K62



K63

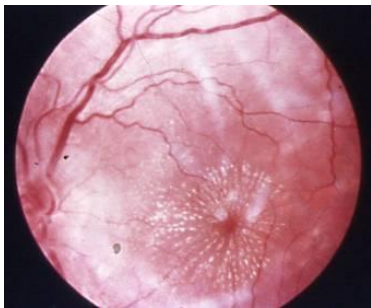

K64

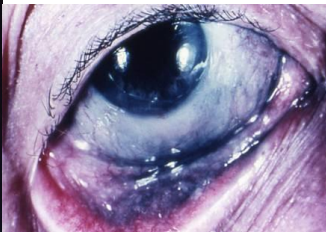
K61 & K62 : Ischaemia of fingers

K63 : Ischaemia of legs

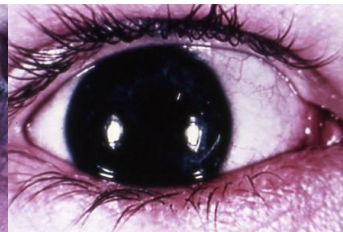
K64 : Ischaemia of toes



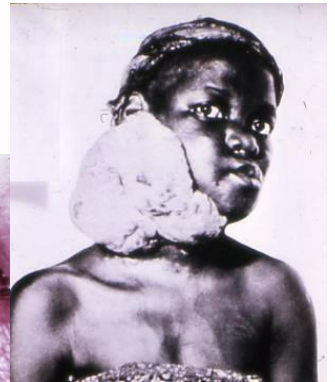K66



K67



K68



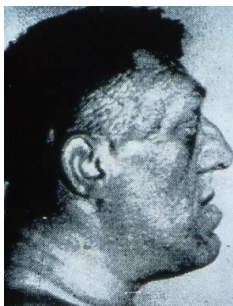K69

K66 : Star exudate of macula / Mâle aet. 31 White / Jules Stein Eye Institute

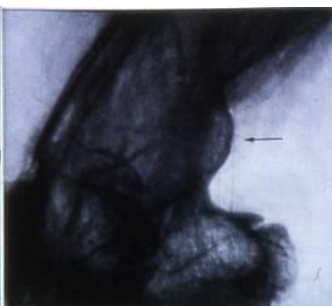
K67 : Iris atrophy / Mâle aet.19 / Jules Stein Eye Institute

K68 : Argyrosis of conjunctiva / Mâle aet.74 / Jules Stein Eye Institute

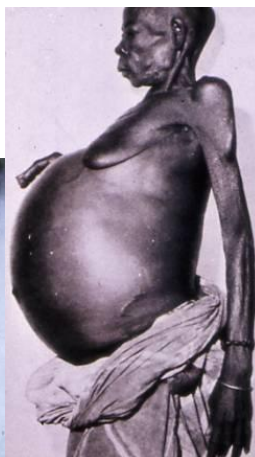K69 : Facial Tumour (cf.)



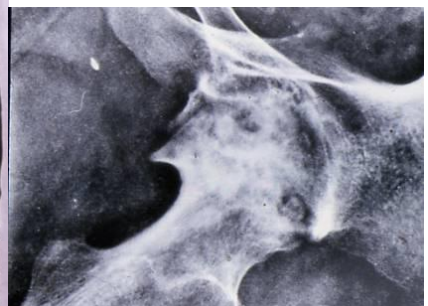
K71



K74



K75



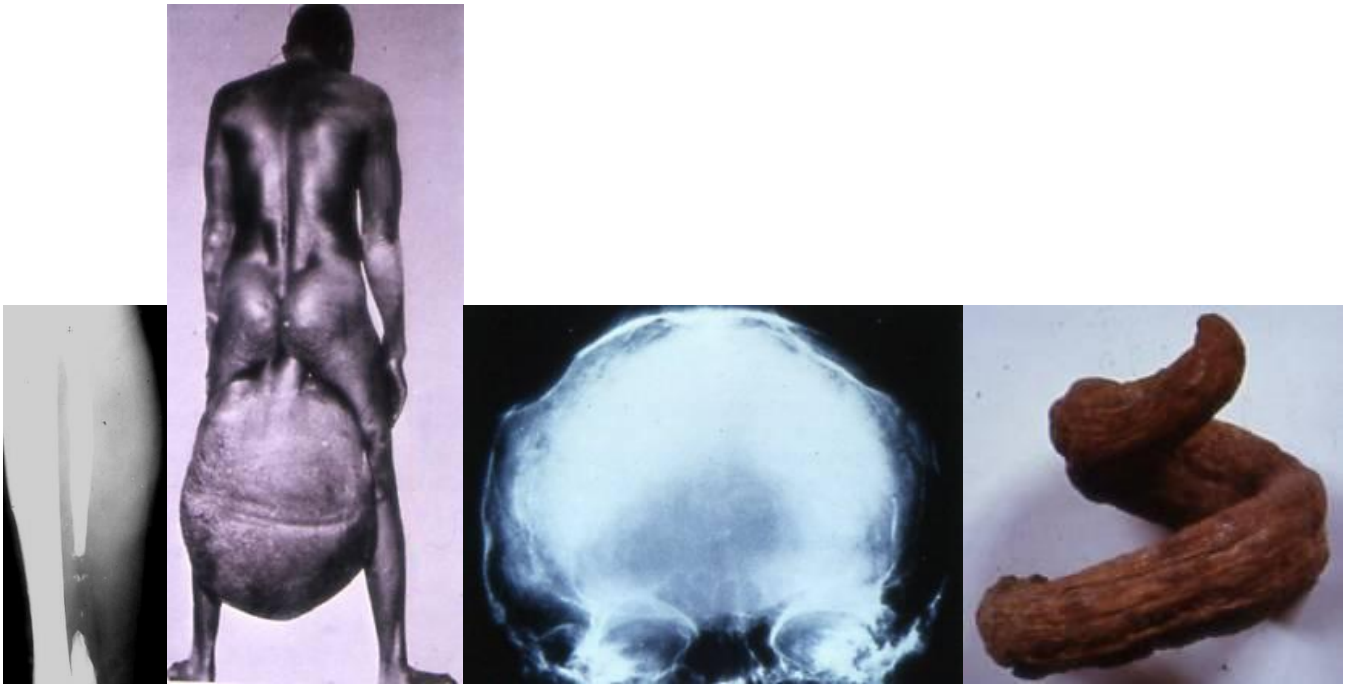
K76

K71 : Acromegaly (cf.K119)

K74 : Fluorosis : Popliteal swelling (radiograph)

K75 : Ovarian cyst

K76 : Hip point necrosis (radiograph)



K77

K78

K79

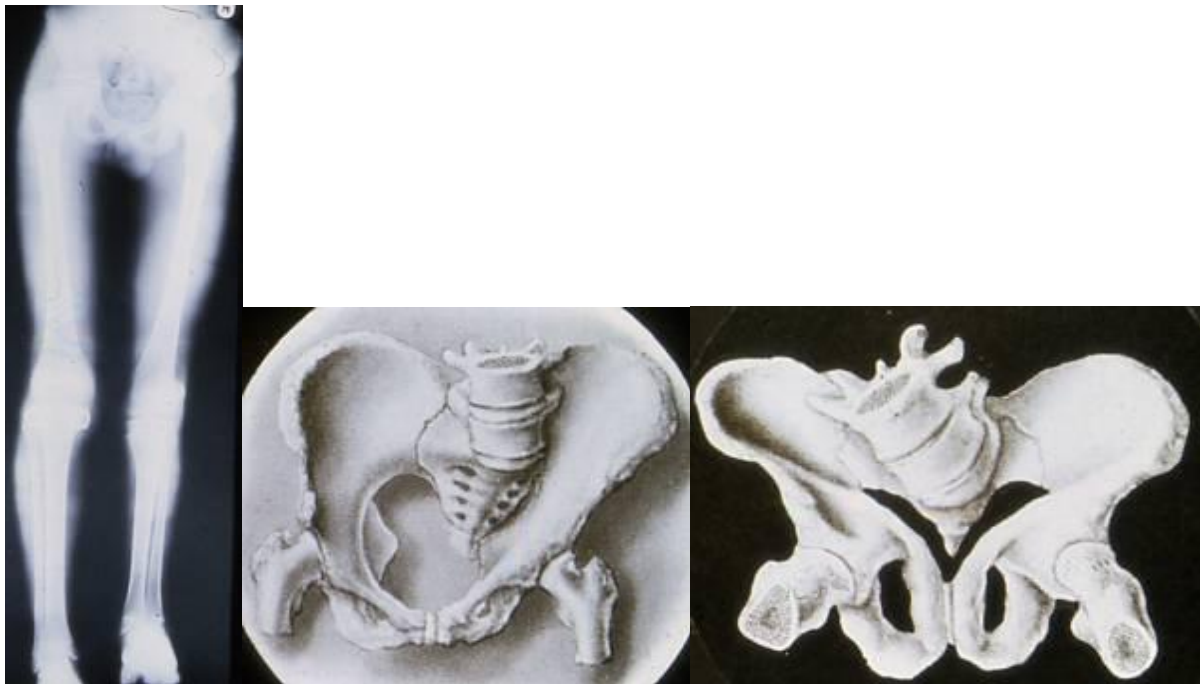
K80

K77 : Hiatus in fibula (radiograph)

K78 : Elephantiasis of scrotum

K79 : "Carpet bag" skull

K80 : Sebaceous Horn / Female aet.73 / Wimbledon 1934



K82

K85

K86

K82 : Poliomyelitis : Scanogram of Lower Limbs

K85 : Naegele pelvis / Model from cast

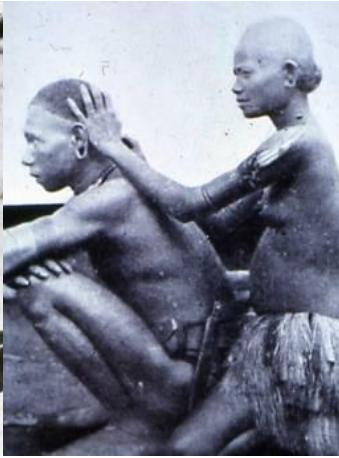K86 : Osteomalacic pelvis / Model from cast



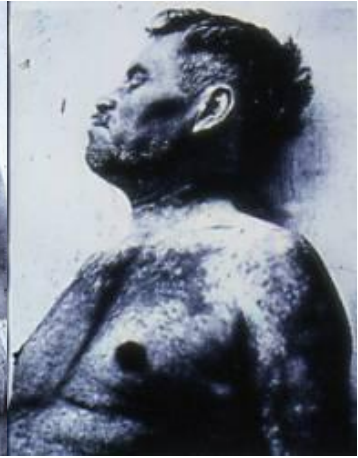K88



K89



K90



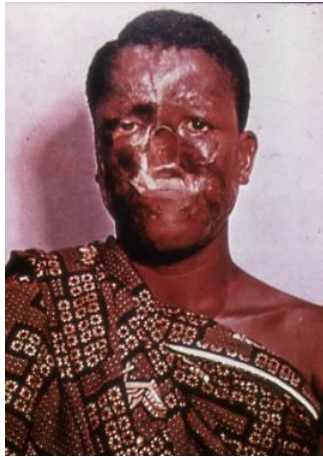
K91

K88 : Negro holding baby

K89 : Australian holding baby

K90 : Louse infestation : Trobriand grooming (Malinowski)

K91 : Pinta : depigmentation of skin)



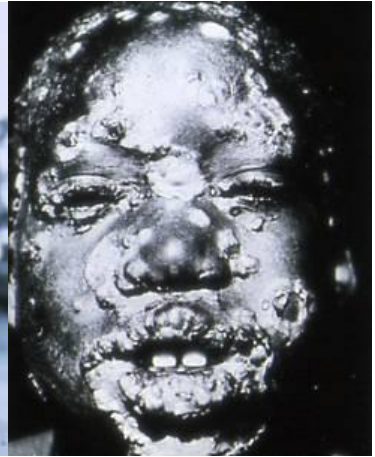K92



K93



K94



K95

K92 : Yaws : gangosa

K93 : Yaws : bone lesions

K94 & 95 : Yaws : gangosa



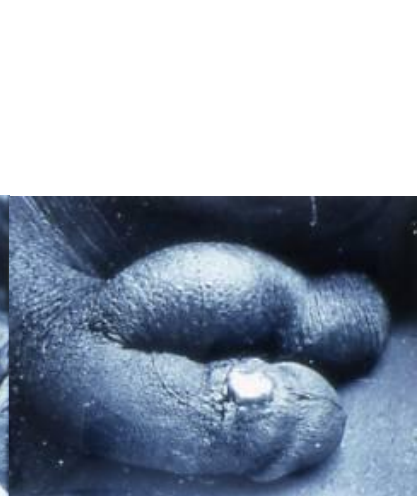K96



K97



K98



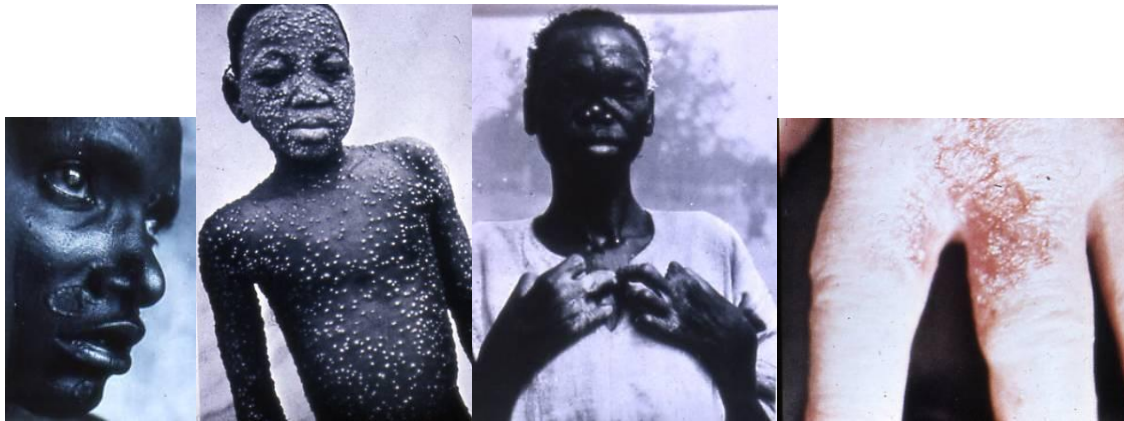K99

K96 : Boomerang legs : female aet.40

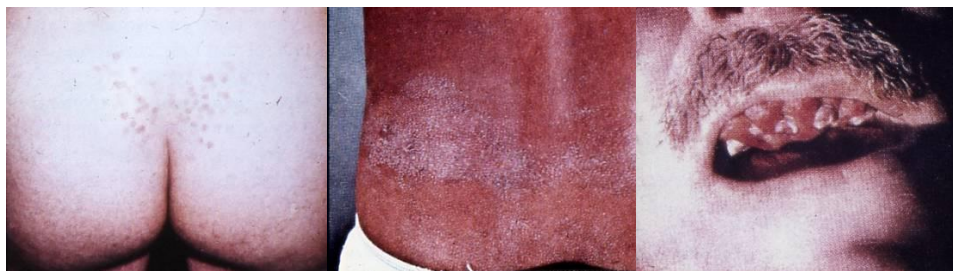K97 : Treponarid : para-articular nodes male aet. 35

K98 : Treponarid :R ash of lip

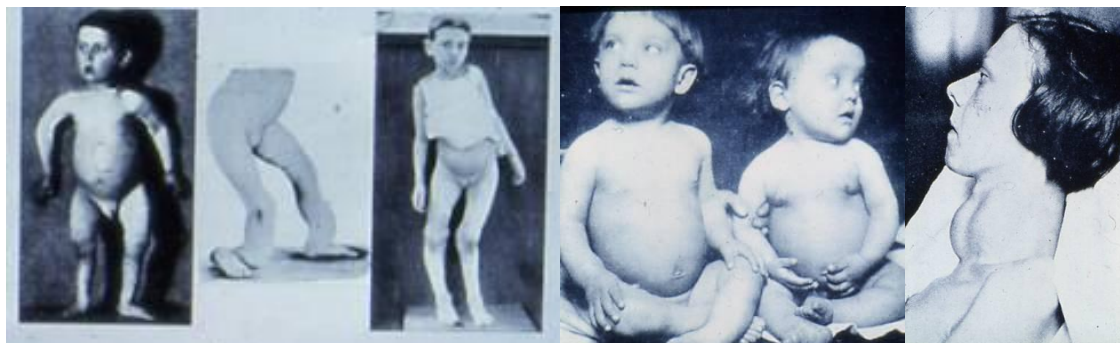K99 : Syphilis : chancre of penis



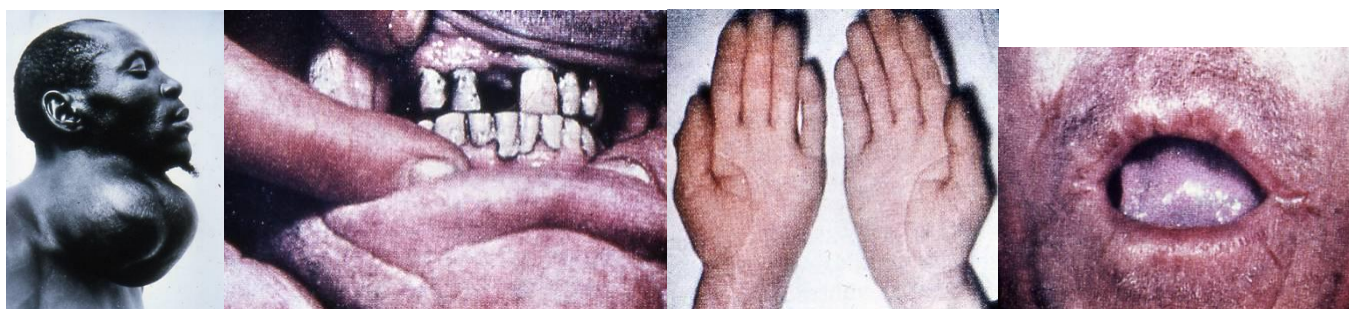
K100 : Syphilis : Skin rash (secondary)
 K101 : Smallpox / African
 K102 : Leprosy : face & fingers loss
 K103 : Dermatitis : Chlorpromazine contact



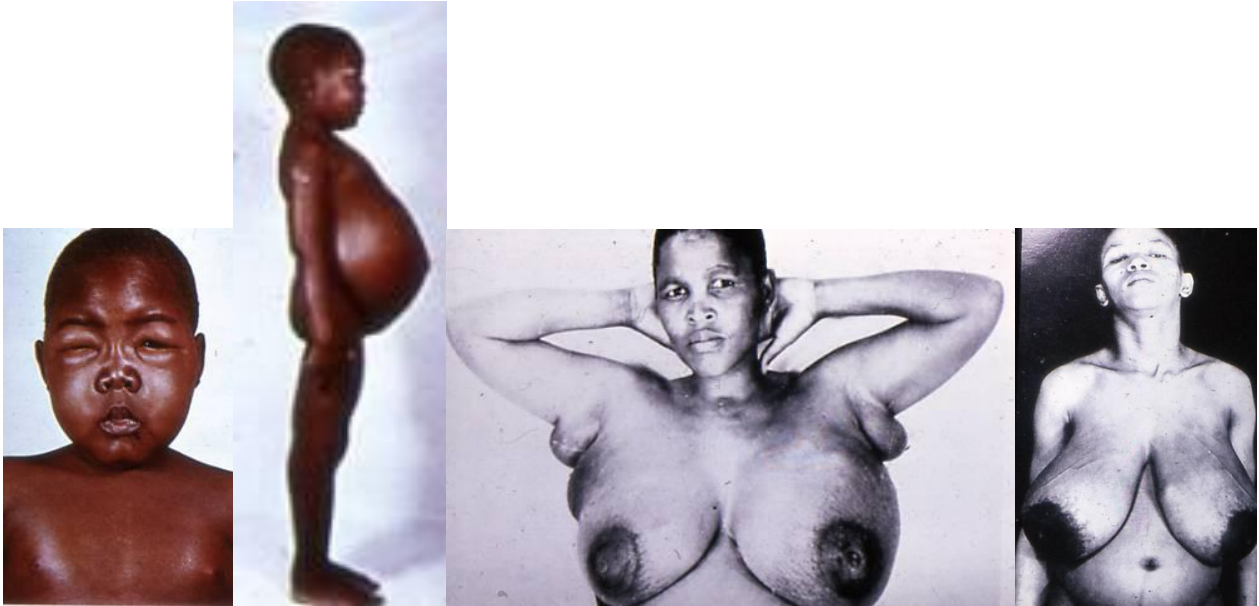K104 : Nickel allergy : Clip of Sanitary belt
 K105 : Dermatitis : Rubber waistband
 K106 : Scurvy



K107 : Rickets / 19th century
 K108 : Rickets / 20th century
 K109 : Goitre, English woman



K110 : Goitre, African man
 K112 : Plumbism : Lead line of gums
 K113 : Yellow hands : surfeit of carrots
 K114 : Ariboflavinosis



K115

K115: Malarial nephrosis / Makonde child
K116 & 117: Hypertrophy of breasts

K116


K117



K118

K119

K118: Leper & Canaanite jar
K119: Acromegaly: Ptolemy coin (cf; K71)



K120

K120: Poliomyelitis (Egyptian stele of Ruma)